

## Orthodontic Induced Inflammatory Root Resorption: The Process Involved and Its Management – A Review of Literature

(Penyerapan Akar Gigi Hasil daripada Keradangan Ortodontik: Proses Terlibat dan Pengurusannya - Tinjauan Kepustakaan)

STEVEN TAN JUN HONG<sup>1</sup>, FARINAWATI YAZID<sup>1</sup>, NURFATHIHA ABU KASIM<sup>2</sup>, SHAHRUL HISHAM ZAINAL ARIFFIN<sup>3</sup> & ROHAYA MEGAT ABDUL WAHAB<sup>1</sup>

<sup>1</sup>*Department of Family Oral Health, Faculty of Dentistry, Universiti Kebangsaan Malaysia, Jalan Raja Muda Abdul Aziz, 50300 Kuala Lumpur, Federal Territory, Malaysia*

<sup>2</sup>*Halvec Laboratories Sdn. Bhd., G-E-4, GF, Enterprise 4, Technology Park Malaysia, Bukit Jalil, 57000 Kuala Lumpur, Federal Territory, Malaysia*

<sup>3</sup>*Department of Biological Sciences and Biotechnology, Faculty of Science and Technology, Universiti Kebangsaan Malaysia, 43600 UKM Bangi, Selangor Darul Ehsan, Malaysia*

*Received: 16 November 2021/Accepted: 9 May 2022*

### ABSTRACT

Orthodontically induced inflammatory root resorption (OIIRR) is inevitable as the force applied during orthodontic treatment to initiate tooth movement induces inflammation, causing iatrogenic root resorption. Even with the use of new technologies in orthodontic appliances, the traumatic effects on the periodontium are still present. Therefore, a proper understanding of the biological aspect of OIIRR such as its pathophysiology and the repair process is crucial to aid in its prevention or minimizing the damage to the apical region. Reported studies related to root resorption in orthodontics and its management until 2022 were searched electronically via PubMed, Scopus, and Google Scholar using keywords such as 'root resorption', 'orthodontic treatment', 'root resorption repair', and 'management'. Other sources were taken from the references of the selected papers. The management of OIIRR has not changed much from the past, which is to temporarily stop the active orthodontic treatment for two to three months and a passive archwire can be used instead. However, interventions such as low-level laser therapy (LLLT), low-intensity pulsed ultrasound (LIPUS), and mechanical vibrational force were introduced to reduce the risk or enhance the healing process of OIIRR. Nevertheless, further studies are warranted to develop a proper usage protocol and the long-term effects of these methods.

Keywords: Low-intensity pulsed ultrasound; low-level laser therapy; orthodontically induced inflammatory root resorption

### ABSTRAK

Penyerapan akar gigi hasil daripada keradangan ortodontik (OIIRR) tidak dapat dielakkan kerana tekanan yang diberikan semasa rawatan ortodontik untuk menggerakkan gigi akan merangsang proses keradangan dan mengakibatkan penyerapan akar gigi iatrogenik. Walaupun dengan penggunaan teknologi baru dalam aplians ortodontik, kesan trauma pada periodontium masih ada. Dengan ini, pemahaman yang tepat mengenai aspek biologi OIIRR seperti patofisiologi dan proses pembaikan OIIRR adalah sangat penting untuk membantu dalam pencegahan atau meminimalkan kerosakan pada kawasan apikal. Kajian yang berkaitan dengan penyerapan akar gigi dalam rawatan ortodontik dan pengurusannya sehingga tahun 2022 telah dicari secara elektronik melalui PubMed, Scopus dan Google Scholar dengan menggunakan kata kunci seperti 'penyerapan akar gigi', 'rawatan ortodontik', 'pembaikan penyerapan akar gigi' dan 'pengurusan rawatan'. Sumber lain juga diambil daripada rujukan yang terdapat dalam artikel terpilih. Pengurusan rawatan untuk OIIRR tidak banyak berubah sejak dahulu, iaitu menghentikan rawatan aktif ortodontik buat sementara selama dua hingga tiga bulan dan boleh memasang wayar arkus secara pasif. Walau bagaimanapun, terdapat kaedah baru seperti terapi laser tahap rendah (LLLT), ultrabunyi denyutan berkeamatan rendah (LIPUS) dan daya getaran mekanikal telah diperkenalkan untuk mengurangkan risiko atau membantu dalam proses penyembuhan OIIRR. Namun, kajian lanjutan diperlukan untuk menentukan protokol penggunaan yang betul dan kesan jangka panjang kaedah tersebut.

Kata kunci: Penyerapan akar gigi hasil daripada keradangan ortodontik; terapi laser tahap rendah; ultrabunyi denyutan berkeamatan rendah

## INTRODUCTION

Brezniak and Wassertein (2002) introduced a new term, 'orthodontically induced inflammatory root resorption' to describe an inevitable pathological event of orthodontic tooth movement, involving the loss of substances from dentine or cementum layer of the root (Kunii et al. 2013; Patel & Ford 2007; Yamaguchi & Fukasawa 2021). It is inevitable as the force applied during orthodontic treatment to initiate tooth movement induces inflammation, causing iatrogenic root resorption and affecting the stability of the teeth (Farah Amirah et al. 2020; Norzaliman Mohd Zain et al. 2020; Rohaya et al. 2017). OIIRR is different from other types of root resorption as it is an extremely complex, sterile inflammatory process that involves various factors including orthodontic forces, morphology of tooth root, alveolar bone, surrounding matrix, and certain known biological messengers (Ballal et al. 2008; Farinawati et al. 2020; Kunii et al. 2013; Zulham et al. 2013).

The prevalence of OIIRR in radiographically examined teeth ranges from 27.7% to 82.11% among orthodontic patients (Bayir & Bolat Gumus 2021; Iglesias-Linares et al. 2016; Li et al. 2020). However, in histologically examined teeth, it has been reported that the prevalence of OIIRR is up to 100% (Harry & Sims 1982; Lu et al. 1999). The large variation is due to several factors such as assessment methods (radiographic or histologic examination) and the definition of root resorption by different authors (Makedonas et al. 2012). Histological examination is much more precise compared to radiographical examination as the root resorption craters can be observed directly, thus, histological studies will have a higher prevalence (Rohaya Megat et al. 2017). The maxillary incisors have been reported to be the most vulnerable to OIIRR, followed by the mandibular incisors (Li et al. 2020; Makedonas et al. 2012; Sameshima & Sinclair 2001). Li et al. (2020) reported the prevalence of OIIRR was 82.11%, the highest OIIRR was found on maxillary lateral incisors (88.52%), followed by mandibular lateral incisors (88.33%), and maxillary central incisors (84.62%). Motokawa et al. (2012) also found a high incidence of OIIRR (78.2%) in their study. Weltman et al. (2010) stated that in most cases of OIIRR, the loss of tooth structure was minimal and clinically insignificant. There was no reported tooth loss due to severe OIIRR, however, as there were limited longitudinal follow-up studies, the risk of severe OIIRR might have been underestimated (Farinawati et al. 2020).

Although new technologies have been introduced to minimize the effect of iatrogenic damage of orthodontic

treatment, the traumatic effects on the periodontium and root structures are still present. This may be due to a lack of understanding of the cellular events of tooth movement (Sabane et al. 2016). Furthermore, recent research has been focused on the risk factors and the detection methods of OIIRR. In comparison, research in the field of the biological aspect of OIIRR is still lacking. A proper understanding of the biological aspect of OIIRR is crucial to aid in its prevention or minimizing the damage to the apical region. Thus, this review article provides a review of the biological aspect of OIIRR as well the latest interventions on OIIRR, besides its suitable timing for intervention and reinstatement of the orthodontic treatment. All reported studies were identified electronically through PubMed, Scopus, and Google Scholar with the keywords of 'root resorption', 'orthodontic treatment', 'root resorption repair', and 'management', covering until the year 2022. The inclusion criteria were (a) clinical trials on animals or humans; (b) studies that are written in English language. The exclusion criteria were (a) studies that are not within the selected keywords (b) no relation to orthodontic management.

## OIIRR CATEGORIZATION

Brezniak and Wasserstein (2002) categorized OIIRR based on the severity of the process clinically into three stages: 1) Cemental or surface resorption: resorption of only the outer cemental layers that has the ability for full regeneration or remodeling, 2) Dentinal resorption: resorption of the cementum and the outer dentinal layers; normally repaired with cementum material in which the root final shape may not be the same with its original form, 3) Circumferential root resorption: circumferential apical root resorption where root shortening is evident. Any apical substance loss beneath the cementum will result in irreversible root shortening where no regeneration is possible.

Earlier, Malmgren et al. (1982) proposed a quantitative assessment of radiographically detected root resorption. The scoring system was initially had 4 grades (Grade 1 to Grade 4). Beck and Harris (1994) then added Grade 0, which is 'no root resorption' into the scoring system. Although this index is relatively subjective, it is commonly used due to its ease of application in daily practice and ability to quantify the degree of root resorption (Makedonas et al. 2012; Pastro et al. 2018). According to the index proposed, there are 5 grades of severity as follow (Figure 1): Grade 0: No root resorption; Grade 1: mild resorption, root with normal length and only displaying an irregular contour; Grade

2: moderate root resorption of less than 2 mm; Grade 3: severe root resorption from 2 mm to one-third of the original root length;

Grade 4: extreme root resorption exceeding one-third of the original root length.

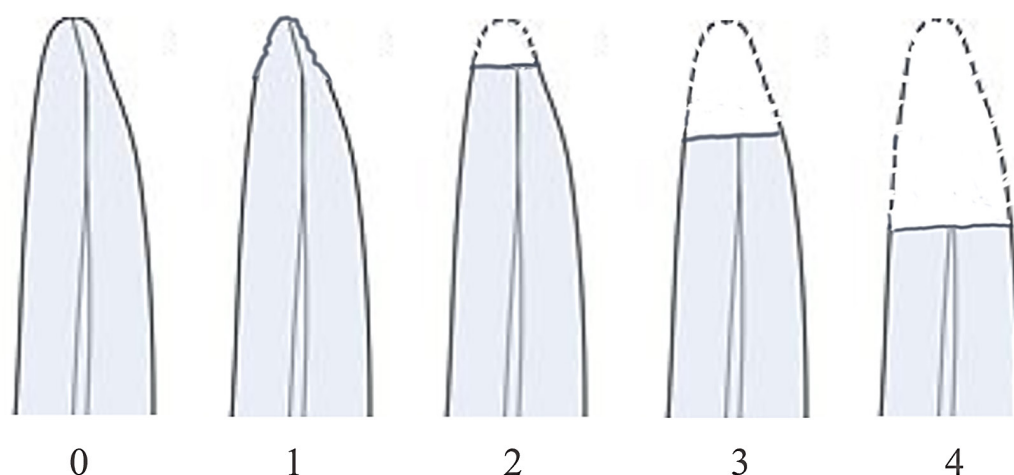


FIGURE 1. Scoring system of Malmgren et al. (1982). Grade 0 was added by Beck and Harris (1994)

#### PATHOPHYSIOLOGY OF OIRR

Orthodontic tooth movement (OTM) is a highly coordinated process that involves effective bone remodeling (Li et al. 2018). When a sustained orthodontic force is loaded onto a tooth, a coupling of bone resorption in the compression side and deposition in tension sides of the periodontal ligament (PDL) take place to facilitate OTM (Krishnan 2017). However, if the force applied exceeds the blood pressure of the capillary bed, it occludes the vasculatures, causing hyalinization (sterile necrosis) of the PDL and surrounding alveolar bone in the compression side (Farinawati et al. 2020).

In order for OTM to continue, these hyalinization sites release various biomolecules that attract macrophage-like cells, multinucleated cells, osteoclasts, and cementoclasts/odontoclasts to resorb the necrotic PDL (Brudvik & Rygh 1995a). Cementoclasts/odontoclasts are multinucleated giant that have a phenotype similar to that of osteoclasts, in contrast to osteoclasts, these cells are mainly involved in resorbing tooth material (Korkmaz et al. 2021; Lira Dos Santos et al. 2021). The resorption of the necrotic PDL can damage the nearby outer layer of the root, which is the cementoblast layer covering the cementoid, leaving a denuded cemental surface that is easily targeted by the odontoclast cells and triggering inflammatory events on the root surface that is

similar to bone resorption (Reitan 1957). The resorption process continues until no remaining hyaline tissues and/or the orthodontic force is ceased. The root surface is also protected by the resorption lacunae which act as a cushion, indirectly reducing the pressure from the orthodontic force. Hence, the cessation of the orthodontic force allows a physiological process where the reversal of the resorption and repair of the cementum can occur (Brudvik & Rygh 1995b). However, in cases where the defect at the root surface is large, the cementum or dentin eventually becomes detached from the root surface as an island. It will be resorbed, and the loss of root structure becomes irreversible, resulting in root shortening (Proffit et al. 2006).

The apical third of the root is the most susceptible region to root resorption and gradually decreased toward the gingival third of the root (Sameshima & Iglesias-Linares 2021). This could be explained by the apical region of the root being lined by cellular cementum, which contains active cells and supporting vasculature, while the cervical region of the root is lined by acellular cementum (Foster 2012). The cellular cementum contains active cells and supporting vasculature, trauma to this region initiates cell injury response, making this region the most vulnerable to root resorption (Henry & Weinmann 1951). This finding was further supported by

Blaushild et al. (1992), who found that the PDL space in the apical region consists of 47% of blood vessels, compared with only 4% at the cervical third of the root. This shows that the apical region has higher metabolic demands and has a more rapid cell turnover than the region with acellular cementum (Abass & Hartsfield 2007). Furthermore, hardness and elastic modulus decrease gradually from the cervical region to the apical region. This makes the apical region of the root has a lower capacity to absorb the applied orthodontic force (Chutimanutskul et al. 2006).

#### THE REPAIR OF OIIRR

The repair of OIIRR commences after interruption of orthodontic force or reduction of the magnitude of the orthodontic force to a certain degree (Cheng et al. 2010). The cementoclasts/odontoclasts undergo apoptosis and detach from the resorption lacunae, and the root repair begins. The fibroblast-like cementoblastic cells invade the resorption crater and produce non-collagenous matrix proteins and collagen fibrils, encapsulating the lacunae with deposition of new cementum and formation of new periodontal ligament (Brudvik & Rygh 1995a, 1995b; Langford & Sims 1982). This process is similar to the early cementogenesis during the development of the teeth. Owmann-Moll and Kuroi (1998) differentiate the extent of root repair histologically into 4 types as follows: 1. No repair, 2. Partial repair - Presence of reparative cementum, either cellular or acellular cementum, at part of the surface of the resorption cavity. 3. Functional repair - Presence of reparative cementum on all the surfaces of the resorption cavity. Original root contour is affected and deformed. 4. Anatomical repair - Presence of reparative cementum on all the surfaces of the resorption cavity. Original root contour is regained.

According to Owmann-Moll et al. (1995), the repair process was seen as early as 1 week after the orthodontic force was discontinued. The amount of repair increased from 28% during the first week to 75% after 8 weeks. Partial repairs (17 to 31%) dominated the repair process during the first 4 weeks of passive retention, 33-40% were functional repairs after 5 to 8 weeks, and after 8 weeks of retention, the repair process was mainly anatomical repairs (12%). These findings were coincidence with the study by Cheng et al. (2010). In their histological study, they reported that the repair process of the samples was mainly functional repairs after 4 weeks of retention and anatomic repairs were seen after 8 weeks of retention. Mehta et al. (2017) also reported that 6 weeks of rest period is adequate only for the functional repair of

resorption craters. These proved that the reparative processes are time-dependent, longer retention time yields the most amount of repair.

Most of the authors agreed that the repair of root resorption craters was achieved by a combination of cellular and acellular cementum (Cheng et al. 2010; Mehta et al. 2017). The acellular type is more often seen in the initial stage of the repair process and followed by the cellular type in the latter stage. Acellular cementum had no Sharpey's fibers and formed very slowly in the bottom of the resorption crater while the cellular cementum contained mixed fibers. As cellular cementum formed at a very fast rate, there were cementocytes trapped in the lacunae before complete mineralization could take place (Cheng et al. 2010).

Regarding the initiation site of the reparative process, most of the authors reported that it was found to begin centrally and extend peripherally (Cheng et al. 2010; Owman-Moll & Kuroi 1998). This is because the central area of the resorption crater has less prominent tissue squeezing between the tooth and the bone surface when compared to the peripheral area which is just adjacent to the bone surface, resulting in more resilience of the tissues. Thus, central area of the resorption crater had more cell proliferation and tissue regeneration (Cheng et al. 2010).

In short, the repair of root resorption is spontaneous and time-dependent, with longer retention or resting period resulting in better healing. It requires at least 8 weeks to achieve an anatomical repair. The repair process involves the deposition of both acellular and cellular cementum. It starts with the deposition of acellular cementum at the centre of the resorption crater and expands to the remaining surface of the crater with deposition of cellular cementum.

#### MANAGEMENT OF OIIRR

Identification of risk factors of OIIRR is crucial at the stage of orthodontic assessment and treatment planning. Brezniak and Wasserstein (2002) divided risk factors into biological and mechanical factors. Biological factors include patient-related factors such as gender, race, genetics, systemic diseases, root morphology, and type of malocclusion. On the other hand, environmental factors like nicotine can increase associated undesired OIIRR and mechanical factors include orthodontic treatment mechanics used to move teeth (Kirschneck et al. 2017). A variety of treatment-related risk factors have been studied such as force magnitude, type and direction of tooth movements, treatment duration and types of

orthodontic appliance. The mechanical factors are of more concern for clinicians as these factors should be under their control, which can be manipulated and amenable via modifications during orthodontic treatment to minimize the severity of OIIRR (Breznia & Wasserstein 2002; Feller et al. 2016; Rohaya et al. 2017).

Various methods have been suggested to minimize the OIIRR, these include limiting the treatment duration, use of light intermittent forces instead of heavy continuous forces and avoiding high-risk tooth movements such as intrusion and torquing the tooth (Shah 2017; Weltman et al. 2010). Recently, some studies highlighted the potential use of biomarkers in the early detection of root resorption, thereby preventing the progression of the process (Farah Amirah et al. 2020; Uma & Nausheer 2018). Various types of biomarkers have been investigated for the use in OIIRR detection, including inflammatory markers (tumour necrosis factor, and interleukins) (Mandour et al. 2020; Rody et al. 2016), bone remodeling markers (receptor activator of nuclear factor kappa B (RANKL)) (Kojima et al. 2013; Yamaguchi et al. 2006), and dentine matrix proteins markers (dentine phosphoprotein (DPP), dentine sialoprotein (DSP), and dentine matrix protein 1 (DMP 1), dentine sialophosphoprotein (DSPP)). Among these biomarkers, several studies agreed on the potential of dentine matrix protein as a specific biological marker for OIIRR (Kereshanan et al. 2008; Lombardo et al. 2016; Mah & Prasad 2004; Yuan et al. 2009). This is due to dentine matrix proteins being highly dentine specific as they are not present in bone, cartilage, soft tissues, or other components of the oral tissues (Butler & Ritchie 1995). The presence of these proteins in PDL space only occurred when the root is undergoing active root resorption as dentine does not undergo remodelling like cementum or the bone (Balducci et al. 2007). Therefore, the concentration of these proteins correlates with the severity of OIIRR. In general, using biomarkers for detection of OIIRR is not only highly sensitive, but a safer method to monitor the OIIRR process compared to conventional radiographic method (Balducci et al. 2007; Farah Amirah et al. 2020; Mah & Prasad 2004; Sha et al. 2014; Uma & Nausheer 2018). Hence, development of a rapid screening tool that is based on biomarkers of root resorption and can be used at chairside could be very helpful to detect root resorption at early stage and monitoring its progress routinely. However, there is no such rapid screening tool available to date, thus, the clinical diagnosis of root resorption is still mostly obtained via radiographic examination (Balducci et al. 2007).

There are some latest interventions to reduce the risk of OIIRR or to enhance its healing process, such as the use of photobiomodulation or low-level laser therapy (LLLT), low-intensity pulsed ultrasound (LIPUS), and mechanical vibrational force. The use of LLLT has shown significantly less root resorption in orthodontic treatment. Nayyer et al. (2021) did a split-mouth, single-blind randomized controlled trial on twenty-two orthodontic patients who required bilaterally maxillary first premolar extractions for orthodontic purposes. For the test group, they applied laser therapy for six times over 28 days, while for the control group, no laser therapy was applied. The premolars were then extracted after 28 days and examined with profilometry, a 3D surface analysis. They reported that there were significantly less amount and volume of resorption craters noted in the test group compared to the control group (Nayyer et al. 2021). This is in coincidence with the study done by Ng et al. (2018), reporting there was a significant decrease in OIIRR in the irradiated group. Ng et al. (2018) also investigated the effect of pulsed and continuous laser therapy, however, no significant difference between those two methods was recorded. Ang Khaw et al. (2018) on the other hand reported that LLLT did not significantly affect OIIRR repair. This might be due to the laser wavelength used in their study being lower (660 nm) compared to the studies by Nayyer et al. (2021) and Ng et al. (2018), which were 980 nm and 808 nm, respectively. Although the optimum dosage of laser wavelength has not been stipulated yet, the use of 660 nm wavelength seems to be insufficient to penetrate and deliver the desired light energy to the target tissues (Ang Khaw et al. 2018). All the studies mentioned above was reflecting the effect of LLLT during the initial stage of orthodontic treatment, thus, further research is needed to investigate the effect of LLLT for the full course of orthodontic treatment as well as the suitable laser wavelength to achieve the desirable results.

Low-intensity pulsed ultrasound (LIPUS) is a non-invasive method that has been shown to enhance the healing process of OIIRR (Al-Daghreer et al. 2014; El-Bialy et al. 2020; Inubushi et al. 2013; Liu et al. 2012). Ultrasound transmits mechanical energy into tissues in a form of pressure waves and can have both diagnostic and therapeutic applications (Tanaka et al. 2015). El-Bialy et al. (2020) carried out a randomized controlled trial with a split-mouth design on 20 patients who required extraction of first premolars. LIPUS with average output intensity of 30 mW/cm<sup>2</sup> was applied for 20 min per day for 24 weeks or until completion of space closure, whichever is shorter.

They used Cone-beam computed tomography (CBCT) images to evaluate the OIIRR of the canines and reported that the rate of OIIRR was significantly decreased at the LIPUS side ( $0.0092 \pm 0.022$  mm/week) compared to the control side ( $0.0223 \pm 0.022$  mm/week). They concluded that LIPUS not only accelerated the orthodontic tooth movement but also significantly reduced the rate of OIIRR (El-Bialy et al. 2020). In another study done by El-Bialy (2004), they applied buccal tipping to the first premolars and simultaneously in a split-mouth design, they applied LIPUS on 1 side and another side was treated as control for 4 weeks. The first premolars were then being extracted and examined with scanning electron microscopy and histologic examination. Their study showed a significant decrease in the areas of resorption and the number of resorption lacunae in the LIPUS-treated premolars. The histologic examination showed increased formation of reparative cementum in LIPUS-treated premolar. Raza et al. (2016) supported this finding as they did a study to evaluate the effect of LIPUS on OIIRR caused by torquing movement. They found that LIPUS-treated teeth had a significantly lesser total volume of resorption lacunae and percentage of root resorption. In short, LIPUS shows to have a positive outcome in enhancing the repair of OIIRR without discontinuing the orthodontic force. Expanded studies on LIPUS can be carried out to determine the threshold of the LIPUS application to reduce the side effects such as pulpal tissue injury due to LIPUS overdose (El-Bialy et al. 2004).

Some authors claimed that supplemental vibration force helps in accelerating orthodontic tooth movement (Leethanakul et al. 2016; Liao et al. 2017; Pavlin et al. 2015), but not many studies were found to report on its effect on OIIRR. Nishimura et al. (2008) applied mechanical vibration onto maxillary first molars of Wistar rats to investigate its effect of it on the speed of orthodontic tooth movement and root resorption. They reported that mechanical vibration can accelerate orthodontic tooth movement without causing damage to periodontal tissues. One interesting finding from their animal study was that there was a trend toward less root resorption in the vibration group. They hypothesised that vibration may have prevented blood flow obstruction and the formation of hyalinization, thereby reducing root resorption (Nishimura et al. 2008). Mayama et al. (2022) tested the effect of vibration on canine retraction in human samples. They concluded that canine retraction was significantly faster with supplementary vibration and there was no significant difference in terms of OIIRR

among the test samples. Similarly, other studies also agreed that there was no significant effect of mechanical vibration force on OIIRR (Dibiase et al. 2016; Yadav et al. 2016; Yilmaz et al. 2021). It is, however, too little evidence to support this conclusion, more studies need to be done to reach a reliable result.

Taking a progress radiograph six to twelve months after orthodontic treatment seems to be important in screening and detecting early OIIRR. If OIIRR is detected, there is a risk that the process of resorption will continue (Artun et al. 2009; Brezniak & Wasserstein 2002; Levander & Malmgren 1988; Sondejker et al. 2020). The practitioner should re-evaluate the initial treatment plan and determine whether the treatment should be continued, modified, or terminated. The decision should be justified based on weighing the risks versus benefits of continuing the treatment as well as the patient's aesthetic perspective. Treatment for malocclusions that will impair oral health on a long-term basis such as deep bite or occlusal trauma should be continued (Sondejker et al. 2020). All the risks and benefits of continuing the treatment should be properly explained to the patient before making the final decisions.

As mentioned before, OIIRR requires at least 8 weeks to achieve an anatomical repair (Cheng et al. 2010; Mehta et al. 2017), thus, it is advisable to temporarily stop the active orthodontic treatment for two to three months to allow the healing of cellular cementum and avoid further progression of root resorption (Levander et al. 1994). During this resting phase, no active orthodontic tooth movement should be applied. This can be done by using a passive archwire or excluding the affected teeth from the active forces. After that resting period and before resuming the active orthodontic treatment, another radiograph should be taken to assess the progression of the OIIRR. If further resorption is detected, treatment plan should be modified to limit tooth movement of the risk tooth. Other treatment options such as prosthetic solutions to close spaces, releasing teeth from active archwires if possible, stripping rather than extracting (to reduce the overall treatment time), and early fixation of resorbed teeth can be considered (Brezniak & Wasserstein 2002; Levander et al. 1994; Sondejker et al. 2020).

If OIIRR is detected in the final radiographs, the patients/guardians should be informed. Follow-up clinical and radiographic examinations should be repeated until the resorption process is halted and stabilized. The cessation of the resorption process and

cemental repair should occur after removal of orthodontic appliances (Copeland & Green 1986; Owman-Moll et al. 1995). If the process is not ceased, root canal therapy with calcium hydroxide should be commenced (Brezniak & Wasserstein 2002; Gholston & Mattison 1983). However, Tirpuwabhurut et al. (2010) did not agree with this suggestion. They reported that there were minimal pulpal changes after extensive orthodontic root resorption. They emphasized that orthodontic root resorptions are not due to infection but the orthodontic forces, hence, management should focus on eliminating the orthodontic forces that caused the inflammation. This inflammation is confined to the compressed PDL, and it does not cause or induce internal root resorption. Therefore, endodontic treatment is not indicated in extensive orthodontic root resorption in the absence of infection as removal of the pulp would not restrict the ongoing root resorption process (Tirpuwabhurut et al. 2010).

Consolaro and Furquim (2014) claimed that a tooth with only the cervical third of the root left might still be able to perform its function in masticatory, speech, and esthetic as it still has 60% of periodontal support. This can be explained by the cervical third has a greater proportion in diameter and circumferential perimeter when compared to the apical region of the root. According to Consolaro and Furquim (2014), teeth with extreme OIIRR can be kept in the dentition and need no replacement with the following conditions: 1. Teeth can be retained in the mouth for aesthetic reasons, without endodontic treatment, except for cases that are exclusively indicated. 2. Any type of occlusal interference must be immediately eliminated to ensure a balanced occlusion. 3. Mouthguard or splint should be prescribed for patients with mild or occasional bruxism and patients who play contact sports such as football and basketball. 4. In cases of trauma to OIIRR teeth, the management protocols used should be the same as those adopted for teeth without root resorption. 5. Biting hard and dense foods, such as whole fruits and bread, should be avoided. 6. Tooth movements of the affected teeth should be avoided as the roots are short. 7. Orthopaedics movements such as mandibular advancement using functional appliance can proceed with conditions that the movements do not involve tooth movements and the supporting structure of the affected teeth, i.e., PDL. 8. Immaculate oral hygiene should be maintained to avoid chronic inflammatory periodontal disease because even slight cervical bone loss in these teeth is very detrimental. 9. Teeth that are

at high risk of causing further root resorption to the affected teeth should be removed, especially when they are partially erupted and tipped against the affected teeth. 10. Parafunctional habits, such as fingernail biting, tongue thrust, object biting, and repetitive contacts with lip and tongue piercings, should be corrected and avoided.

#### CONCLUSION

Orthodontically induced inflammatory root resorption is an unavoidable sequela of orthodontic treatment. Besides risk factors related to OIIRR, clinicians should be able to understand the basic cellular events of tooth movement and biological aspect of OIIRR is crucial to aid in its prevention or minimizing the damage to the apical region. There are many interventions introduced to reduce the risk of OIIRR or enhance the healing process of OIIRR such as LLLT, LIPUS, and mechanical vibrational force, however, further studies are warranted to develop a proper usage protocol and long-term effects of these methods.

It is advisable to take progressive radiographs during the orthodontic treatment for those teeth with increased risk of OIIRR. If OIIRR is detected, clinicians should temporarily stop the active orthodontic treatment for two to three months and a passive archwire can be used instead to allow the healing of cellular cementum to avoid further progression of root resorption. Modifications of the initial treatment plan should be advocated in cases where progressive OIIRR are detected.

#### ACKNOWLEDGEMENTS

The authors would like to thank the Faculty of Dentistry, Universiti Kebangsaan Malaysia for the financial grant (DD-2021-005) and for supporting this study.

#### REFERENCES

- Abass, S. & Hartsfield, J. 2007. Orthodontics and external apical root resorption. *Seminars in Orthodontics* 13: 246-256.
- Al-Daghreer, S., Doschak, M., Sloan, A.J., Major, P.W., Heo, G., Scurtescu, C., Tsui, Y.Y. & El-Bialy, T. 2014. Effect of low-intensity pulsed ultrasound on orthodontically induced root resorption in beagle dogs. *Ultrasound Med. Biol.* 40(6): 1187-1196.
- Ang Khaw, C.M., Dalci, O., Foley, M., Petocz, P., Darendeliler, M.A. & Papadopoulou, A.K. 2018. Physical properties of root cementum: Part 27. Effect of low-level laser therapy on the repair of orthodontically induced inflammatory root resorption: A double-blind, split-mouth, randomized controlled clinical trial. *Am. J. Orthod. Dentofacial Orthop.* 154(3): 326-336.

- Artun, J., Van 't Hulleenaar, R., Doppel, D. & Kuijpers-Jagtman, A.M. 2009. Identification of orthodontic patients at risk of severe apical root resorption. *Am. J. Orthod. Dentofacial Orthop.* 135(4): 448-455.
- Balducci, L., Ramachandran, A., Hao, J., Narayanan, K., Evans, C. & George, A. 2007. Biological markers for evaluation of root resorption. *Archives of Oral Biology* 52(3): 203-208.
- Ballal, V., Kundabala, M. & Bhat, K.S. 2008. Nonsurgical management of a nonvital tooth with orthodontically induced external root resorption and extensive periapical pathology. *American Journal of Orthodontics and Dentofacial Orthopedics* 134(1): 149-152.
- Bayir, F. & Bolat Gumus, E. 2021. External apical root resorption after orthodontic treatment: incidence, severity and risk factors. *J. Dent. Res. Dent. Clin. Dent. Prospects* 15(2): 100-105.
- Beck, B.W. & Harris, E.F. 1994. Apical root resorption in orthodontically treated subjects: Analysis of edgewise and light wire mechanics. *American Journal of Orthodontics and Dentofacial Orthopedics* 105(4): 350-361.
- Blaushild, N., Michaeli, Y. & Steigman, S. 1992. Histomorphometric study of the periodontal vasculature of the rat incisor. *Journal of Dental Research* 71(12): 1908-1912.
- Brezniak, N. & Wasserstein, A. 2002. Orthodontically induced inflammatory root resorption. Part I: The basic science aspects. *The Angle Orthodontist* 72(2): 175-179.
- Brezniak, N. & Wasserstein, A. 2002. Orthodontically induced inflammatory root resorption. Part II: The clinical aspects. *Angle. Orthod.* 72(2): 180-184.
- Brudvik, P. & Rygh, P. 1995a. The repair of orthodontic root resorption: An ultrastructural study. *Eur. J. Orthod.* 17(3): 189-198.
- Brudvik, P. & Rygh, P. 1995b. Transition and determinants of orthodontic root resorption-repair sequence. *Eur. J. Orthod.* 17(3): 177-188.
- Butler, W.T. & Ritchie, H. 1995. The nature and functional significance of dentin extracellular matrix proteins. *Int. J. Dev. Biol.* 39(1): 169-179.
- Cheng, L.L., Türk, T., Elekdağ-Türk, S., Jones, A.S., Yu, Y. & Darendeliler, M.A. 2010. Repair of root resorption 4 and 8 weeks after application of continuous light and heavy forces on premolars for 4 weeks: A histology study. *Am. J. Orthod. Dentofacial Orthop.* 138(6): 727-734.
- Chutimanutskul, W., Darendeliler, M.A., Shen, G., Petocz, P. & Swain, M. 2006. Changes in the physical properties of human premolar cementum after application of 4 weeks of controlled orthodontic forces. *Eur. J. Orthod.* 28: 313-318.
- Consolaro, A. & Furquim, L.Z. 2014. Extreme root resorption associated with induced tooth movement: A protocol for clinical management. *Dental Press J. Ortho.* 19(5): 19-26.
- Copeland, S. & Green, L.J. 1986. Root resorption in maxillary central incisors following active orthodontic treatment. *Am. J. Orthod.* 89(1): 51-55.
- Dibiase, A.T., Woodhouse, N.R., Papageorgiou, S.N., Johnson, N., Slipper, C., Grant, J., Alsaleh, M. & Cobourne, M.T. 2016. Effect of supplemental vibrational force on orthodontically induced inflammatory root resorption: A multicenter randomized clinical trial. *Am. J. Orthod. Dentofacial Orthop.* 150(6): 918-927.
- El-Bialy, T., El-Shamy, I. & Graber, T.M. 2004. Repair of orthodontically induced root resorption by ultrasound in humans. *Am. J. Orthod. Dentofacial Orthop.* 126(2): 186-193.
- El-Bialy, T., Farouk, K., Carlyle, T.D., Wiltshire, W., Drummond, R., Dumore, T., Knowlton, K. & Tompson, B. 2020. Effect of low intensity pulsed ultrasound (LIPUS) on tooth movement and root resorption: A prospective multi-center randomized controlled trial. *J. Clin. Med.* 9(3): 804.
- Farah Amirah, M.N., Shahrul Hisham, Z.A., Saiful Anuar, K. & Rohaya Megat, A.W. 2020. Label-free quantitative proteomic analysis of gingival crevicular fluid to identify potential early markers for root resorption. *BMC Oral Health* 20(1): 256.
- Farinawati, Y., Teh, Y., Asma, A., Shahrul Hisham, Z.A. & Rohaya Megat, A.W. 2020. Detection methods of orthodontically induced inflammatory root resorption (OIIRR): A review. *Australasian Orthodontic Journal* 36: 101-107.
- Feller, L., Khammissa, R.A., Thomadakis, G., Fourie, J. & Lemmer, J. 2016. Apical external root resorption and repair in orthodontic tooth movement: Biological events. *Biomed. Res. Int.* 2016: 4864195.
- Foster, B.L. 2012. Methods for studying tooth root cementum by light microscopy. *International Journal of Oral Science* 4(3): 119-128.
- Gholston, L.R. & Mattison, G.D. 1983. An endodontic-orthodontic technique for esthetic stabilization of externally resorbed teeth. *Am. J. Orthod.* 83(5): 435-440.
- Harry, M.R. & Sims, M.R. 1982. Root resorption in bicuspid intrusion. A scanning electron microscope study. *Angle Orthod.* 52(3): 235-258.
- Henry, J.L. & Weinmann, J.P. 1951. The pattern of resorption and repair of human cementum. *J. Am. Dent. Assoc.* 42(3): 270-290.
- Iglesias-Linares, A., Sonnenberg, B., Solano, B., Yañez-Vico, R.M., Solano, E., Lindauer, S.J. & Flores-Mir, C. 2016. Orthodontically induced external apical root resorption in patients treated with fixed appliances vs removable aligners. *The Angle Orthodontist* 87(1): 3-10.
- Inubushi, T., Tanaka, E., Rego, E.B., Ohtani, J., Kawazoe, A., Tanne, K., Miyauchi, M. & Takata, T. 2013. Ultrasound stimulation attenuates resorption of tooth root induced by experimental force application. *Bone* 53(2): 497-506.



- Kereshanan, S., Stephenson, P. & Waddington, R. 2008. Identification of dentine sialoprotein in gingival crevicular fluid during physiological root resorption and orthodontic tooth movement. *Eur. J. Orthod.* 30(3): 307-314.
- Kirschneck, C., Maurer, M., Wolf, M., Reicheneder, C. & Proff, P. 2017. Regular nicotine intake increased tooth movement velocity, osteoclastogenesis and orthodontically induced dental root resorptions in a rat model. *Int. J. Oral. Sci.* 9(3): 174-184.
- Kojima, T., Yamaguchi, M., Yoshino, T., Shimizu, M., Yamada, K., Goseki, T. & Kasai, K. 2013. Tnf- A and RANKL facilitates the development of orthodontically-induced inflammatory root resorption. *Open Journal of Stomatology* 3: 52-58.
- Korkmaz, Y., Puladi, B., Galler, K., Kämmerer, P.W., Schröder, A., Gölz, L., Sparwasser, T., Bloch, W., Friebe, A. & Deschner, J. 2021. Inflammation in the human periodontium induces downregulation of the A1- and B1-subunits of the sGC in cementoclasts. *International Journal of Molecular Sciences* 22(2): 539.
- Krishnan, V. 2017. Root resorption with orthodontic mechanics: Pertinent areas revisited. *Australian Dental Journal* 62(S1): 71-77.
- Kunii, R., Yamaguchi, M., Tanimoto, Y., Asano, M., Yamada, K., Goseki, T. & Kasai, K. 2013. Role of interleukin-6 in orthodontically induced inflammatory root resorption in humans. *Korean Journal of Orthodontics* 43(6): 294-301.
- Langford, S.R. & Sims, M.R. 1982. Root surface resorption, repair, and periodontal attachment following rapid maxillary expansion in man. *Am. J. Orthod.* 81(2): 108-115.
- Leethanakul, C., Suamphan, S., Jitpukdeebodindra, S., Thongudomporn, U. & Charoemratrote, C. 2016. Vibratory stimulation increases interleukin-1 beta secretion during orthodontic tooth movement. *Angle Orthod.* 86(1): 74-80.
- Levander, E. & Malmgren, O. 1988. Evaluation of the risk of root resorption during orthodontic treatment: A study of upper incisors. *Eur. J. Orthod.* 10(1): 30-38.
- Levander, E., Malmgren, O. & Eliasson, S. 1994. Evaluation of root resorption in relation to two orthodontic treatment regimes. A clinical experimental study. *Eur. J. Orthod.* 16(3): 223-228.
- Li, Y., Deng, S., Mei, L., Li, Z., Zhang, X., Yang, C. & Li, Y. 2020. Prevalence and severity of apical root resorption during orthodontic treatment with clear aligners and fixed appliances: A cone beam computed tomography study. *Progress in Orthodontics* 21(1): 1.
- Li, Y., Jacox, L.A., Little, S.H. & Ko, C.C. 2018. Orthodontic tooth movement: The biology and clinical implications. *Kaohsiung J. Med. Sci.* 34(4): 207-214.
- Liao, Z., Elekdag-Turk, S., Turk, T., Grove, J., Dalci, O., Chen, J., Zheng, K., Ali Darendeliler, M., Swain, M. & Li, Q. 2017. Computational and clinical investigation on the role of mechanical vibration on orthodontic tooth movement. *J. Biomech.* 60: 57-64.
- Lira Dos Santos, E.J., De Almeida, A.B., Chavez, M.B., Salmon, C.R., Mofatto, L.S., Camara-Souza, M.B., Tan, M.H., Kolli, T.N., Mohamed, F.F., Chu, E.Y., Novaes, P.D., Santos, E.C.A., Kantovitz, K.R., Foster, B.L. & Nociti, F.H. 2021. Orthodontic tooth movement alters cementocyte ultrastructure and cellular cementum proteome signature. *Bone* 153: 116139.
- Liu, Z., Xu, J., E. L. & Wang, D. 2012. Ultrasound enhances the healing of orthodontically induced root resorption in rats. *Angle Orthod.* 82(1): 48-55.
- Lombardo, L., Carinci, F., Martini, M., Gemmati, D., Nardone, M. & Siciliani, G. 2016. Quantitative evaluation of dentin sialoprotein (Dsp) using microbeads - A potential early marker of root resorption. *ORAL & Implantology* 9(3): 132-142.
- Lu, L.H., Lee, K., Imoto, S., Kyomen, S. & Tanne, K. 1999. Histological and histochemical quantification of root resorption incident to the application of intrusive force to rat molars. *Eur. J. Orthod.* 21(1): 57-63.
- Mah, J. & Prasad, N. 2004. Dentine phosphoproteins in gingival crevicular fluid during root resorption. *Eur. J. Orthod.* 26(1): 25-30.
- Makedonas, D., Lund, H. & Hansen, K. 2012. Root resorption diagnosed with cone beam computed tomography after 6 Months and at the end of orthodontic treatment with fixed appliances. *The Angle Orthodontist* 83(3): 389-393.
- Malmgren, O., Goldson, L., Hill, C., Orwin, A., Petrini, L. & Lundberg, M. 1982. Root resorption after orthodontic treatment of traumatized teeth. *American Journal of Orthodontics* 82(6): 487-491.
- Mandour, K.A.A., Tawfeek, M.A. & Montasser, M.A. 2020. Expression of biological markers in gingival crevicular fluid of teeth with orthodontically induced root resorption. *Journal of Orofacial Orthopedics/Fortschritte der Kieferorthopädie* 82(5): 313-320.
- Mayama, A., Seiryu, M. & Takano-Yamamoto, T. 2022. Effect of vibration on orthodontic tooth movement in a double blind prospective randomized controlled trial. *Scientific Reports* 12(1): 1288.
- Mehta, S.A., Deshmukh, S.V., Sable, R.B. & Patil, A.S. 2017. Comparison of 4 and 6 weeks of rest period for repair of root resorption. *Prog. Orthod.* 18(1): 18.
- Motokawa, M., Sasamoto, T., Kaku, M., Kawata, T., Matsuda, Y., Terao, A. & Tanne, K. 2012. Association between root resorption incident to orthodontic treatment and treatment factors. *European Journal of Orthodontics* 34(3): 350-356.
- Nayyer, N., Tripathi, T., Rai, P. & Kanase, A. 2021. Effect of photobiomodulation on external root resorption during orthodontic tooth movement – A randomized controlled trial. *International Orthodontics* 19(2): 197-206.
- Ng, D., Chan, A.K., Papadopoulou, A.K., Dalci, O., Petocz, P. & Darendeliler, M.A. 2018. The effect of low-level laser therapy on orthodontically induced root resorption: A pilot double blind randomized controlled trial. *European Journal of Orthodontics* 40(3): 317-325.

- Nishimura, M., Chiba, M., Ohashi, T., Sato, M., Shimizu, Y., Igarashi, K. & Mitani, H. 2008. Periodontal tissue activation by vibration: Intermittent stimulation by resonance vibration accelerates experimental tooth movement in rats. *Am. J. Orthod. Dentofacial Orthop.* 133(4): 572-583.
- Norzaliman Mohd Zain, M., Yusof, Z., Yazid, F., Ashari, A., Wong, K., Lee, W., Tan, K., Ariffin, S. & Megat Abdul Wahab, R. 2020. Absorption spectrum analysis of dentine sialophosphoprotein (DSPP) in orthodontic patient. *AIP Conference Proceedings* 2203: 020007. <https://doi.org/10.1063/1.5142099>
- Owman-Moll, P. & Kurol, J. 1998. The early reparative process of orthodontically induced root resorption in adolescents-Location and type of tissue. *Eur. J. Orthod.* 20(6): 727-732.
- Owman-Moll, P., Kurol, J. & Lundgren, D. 1995. Repair of orthodontically induced root resorption in adolescents. *Angle Orthod.* 65(6): 403-408; discussion 409-410.
- Pastro, J., Nogueira, A., Freitas, K.M., Valarelli, F., Cançado, R., Oliveira, R. & Oliveira, R. 2018. Factors associated to apical root resorption after orthodontic treatment. *The Open Dentistry Journal* 12: 331-339.
- Patel, S. & Ford, T. 2007. Is the resorption external or internal? *Dental Update* 34: 218-220, 222, 224.
- Pavlin, D., Anthony, R., Raj, V. & Gakunga, P.T. 2015. Cyclic loading (vibration) accelerates tooth movement in orthodontic patients: A double-blind, randomized controlled trial. *Seminars in Orthodontics* 21(3): 187-194.
- Proffit, W.R., Fields Jr., H.W. & Sarver, D.M. 2006. *Contemporary Orthodontics*. 6th. Elsevier Health Sciences.
- Raza, H., Major, P., Dederich, D. & El-Bialy, T. 2016. Effect of low-intensity pulsed ultrasound on orthodontically induced root resorption caused by torque: A prospective, double-blind, controlled clinical trial. *Angle Orthod.* 86(4): 550-557.
- Reitan, K. 1957. Some factors determining the evaluation of forces in orthodontics. *American Journal of Orthodontics* 43(1): 32-45.
- Rody Jr., W.J., Wijegunasinghe, M., Holliday, L.S., Mchugh, K.P. & Wallet, S.M. 2016. Immunoassay analysis of proteins in gingival crevicular fluid samples from resorbing teeth. *Angle Orthod.* 86(2): 187-192.
- Rohaya, M.A.W., Noor Ayuni, A.S. & Shahrul Hisham, Z.A. 2017. An insight into risk factors for root resorption during orthodontic treatment. *Journal of Medical Sciences* 17: 1-9.
- Sabane, A., Patil, A., Swami, V. & Nagarajan, P. 2016. Biology of tooth movement. *British Journal of Medicine and Medical Research* 16: 1-10.
- Sameshima, G.T. & Iglesias-Linares, A. 2021. Orthodontic root resorption. *Journal of the World Federation of Orthodontists* 10(4): 135-143.
- Sameshima, G.T. & Sinclair, P.M. 2001. Predicting and preventing root resorption: Part I. Diagnostic factors. *Am. J. Orthod. Dentofacial Orthop.* 119(5): 505-510.
- Sha, H., Bai, Y., Li, S., Wang, X. & Yin, Y. 2014. Comparison between electrochemical elisa and spectrophotometric elisa for the detection of dentine sialophosphoprotein for root resorption. *Am. J. Orthod. Dentofacial Orthop.* 145(1): 36-40.
- Shah, A. 2017. Orthodontically induced root resorption-A review. *International Journal for Advance Research and Development* 2(1).
- Sondeijker, C.F.W., Lamberts, A.A., Beckmann, S.H., Kuitert, R.B., Van Westing, K., Persoon, S. & Kuijpers-Jagtman, A.M. 2020. Development of a clinical practice guideline for orthodontically induced external apical root resorption. *Eur. J. Orthod.* 42(2): 115-124.
- Tanaka, E., Kuroda, S., Horiuchi, S., Tabata, A. & El-Bialy, T. 2015. Low-intensity pulsed ultrasound in dentofacial tissue engineering. *Ann. Biomed. Eng.* 43(4): 871-886.
- Tripuwabhut, P., Brudvik, P., Fristad, I. & Rethnam, S. 2010. Experimental orthodontic tooth movement and extensive root resorption: Periodontal and pulpal changes. *Eur. J. Oral Sci.* 118(6): 596-603.
- Uma, H. & Nausheer, A. 2018. Identification of dentine sialophosphoprotein in gingival crevicular fluid to assess root resorption using three piece base arch. *IOSR Journal of Dental and Medical Sciences (IOSR-JDMS)* 17(1): 56-63.
- Weltman, B., Vig, K.W., Fields, H.W., Shanker, S. & Kaizar, E.E. 2010. Root resorption associated with orthodontic tooth movement: A systematic review. *Am. J. Orthod. Dentofacial Orthop.* 137(4): 462-476; discussion 412A.
- Yadav, S., Dobie, T., Assefnia, A., Kalajzic, Z. & Nanda, R. 2016. The effect of mechanical vibration on orthodontically induced root resorption. *Angle Orthod.* 86(5): 740-745.
- Yamaguchi, M., Aihara, N., Kojima, T. & Kasai, K. 2006. RANKL increase in compressed periodontal ligament cells from root resorption. *Journal of Dental Research* 85(8): 751-756.
- Yamaguchi, M. & Fukasawa, S. 2021. Is Inflammation a friend or foe for orthodontic treatment?: Inflammation in orthodontically induced inflammatory root resorption and accelerating tooth movement. *International Journal of Molecular Sciences* 22(5): 2388.
- Yilmaz, H., Ozlu, F.C., Turk, T. & Darendeliler, M.A. 2021. The effect of 12 weeks of mechanical vibration on root resorption: A micro-Ct study. *Progress in Orthodontics* 22(1): 28.
- Yuan, G., Wang, Y., Gluhak-Heinrich, J., Yang, G., Chen, L., Li, T., Wu, L.A., Chen, Z., Macdougall, M. & Chen, S. 2009. Tissue-specific expression of dentin sialophosphoprotein (DSPP) and its polymorphisms in mouse tissues. *Cell Biology International* 33(8): 816-829.

Zulham, Y., Ikmal, M.J., Rohaya, M.A.W., Intan Zarina, Z.A., Sahidan, S., Zaidah, Z.A. & Shahrul Hisham, Z.A. 2013. Orthodontic treatment effects on inflammatory marker profiles in saliva before and after 2 archwire changes. *AIP Conference Proceedings* 1571: 208. <https://doi.org/10.1063/1.4858656>

\*Corresponding author; email: [rohaya\\_megat@ukm.edu.my](mailto:rohaya_megat@ukm.edu.my)